

CORRESPONDENCE



Acute Coronary Thrombosis in Boston Marathon Runners

TO THE EDITOR: Regular exercise reduces the incidence of coronary atherosclerotic disease and decreases mortality after myocardial infarction,¹ but vigorous activity increases the risk of myocardial infarction and sudden death among patients with occult and diagnosed coronary artery disease.^{2,3} We describe three male athletes in good condition without diagnosed coronary artery disease who presented with acute coronary thrombosis immediately after completing the 2011 Boston Marathon (Fig. 1).

The first patient was a 45-year-old man in whom chest pressure developed 15 minutes after he completed the marathon, leading to the diagnosis of an anterior ST-segment elevation myocardial infarction (STEMI). Coronary angiography (Fig. 1A and 1B) showed a proximal 70% stenosis of the left anterior descending artery with a heavy thrombus burden. After successful aspiration thrombectomy, intravascular ultrasonographic examination confirmed a ruptured plaque, which required a single stent.

In the second patient, a 55-year-old man, chest burning developed 5 minutes after he completed the marathon, and an anterior STEMI was diagnosed. Coronary angiographic examination (Fig. 1C and 1D) showed a 100% proximal left anterior descending thrombus requiring placement of a single coronary stent.

The third patient, a 49-year-old man, lost consciousness 15 minutes after completing the marathon. Electrocardiographic testing showed an inferior STEMI. Coronary angiographic examination (Fig. 1E and 1F) revealed severe, three-vessel coronary disease and an occlusive thrombus in the left circumflex artery. The left circumflex artery was treated with three coronary stents. Refractory cardiogenic shock necessitated placement of an intraaortic balloon pump and an Impella 2.5 left percutaneous cardiac-support device (Abiomed). He recovered and was discharged home after 8 days of hospitalization.

We identified three runners in whom acute coronary thrombosis developed within minutes after completing the 2011 Boston Marathon. Exercise-induced coronary-plaque rupture was first described nearly four decades ago, and it has been attributed to increased flexing of atherosclerotic coronary arteries during exertion.⁴ Symptoms in the present runners developed shortly after they finished the race. Thrombotic factors may increase after exercise, provoking thrombosis in a plaque ruptured during exertion.

All three runners in our series arrived by airplane, with a minimum flight time of 4 hours. Runners who flew more than 4 hours to the 2010 Boston Marathon had elevated concentrations of thrombin-antithrombin complex as compared with runners who drove less than 2 hours to the race.⁵

THIS WEEK'S LETTERS

- 184 Acute Coronary Thrombosis in Boston Marathon Runners
- 185 An Impedance Threshold Device in Out-of-Hospital Cardiac Arrest
- 188 Breast-Cancer Adjuvant Therapy with Zoledronic Acid
- 190 Inflammatory Bowel Disease and ADAM17 Deletion
- 190 Breast-Cancer Screening
- 192 Generalizing Lung-Cancer Screening Results

Approximately 500,000 runners ran a marathon in the United States in 2010. Although the risk of marathon-related sudden death is estimated to be 1 in 50,000 participants, our findings show that exercise-related acute coronary thrombosis may occur immediately after exercise and that further investigation into risk factors for thrombosis in marathon runners is required.

Alfred J. Albano, M.D.

Tufts Medical Center
Boston, MA

Paul D. Thompson, M.D.

Hartford Hospital
Hartford, CT

Navin K. Kapur, M.D.

Tufts Medical Center
Boston, MA
nkapur@tuftsmedicalcenter.org

Disclosure forms provided by the authors are available with the full text of this letter at NEJM.org.

1. Thompson PD, Buchner D, Pina IL, et al. Exercise and physical activity in the prevention and treatment of atherosclerotic cardiovascular disease: a statement from the Council on Clinical Cardiology (Subcommittee on Exercise, Rehabilitation, and Prevention) and the Council on Nutrition, Physical Activity, and Metabolism (Subcommittee on Physical Activity). *Circulation* 2003;107:3109-16.
2. Siscovick DS, Weiss NS, Fletcher RH, Lasky T. The incidence of primary cardiac arrest during vigorous exercise. *N Engl J Med* 1984;311:874-7.
3. Mittleman MA, Maclure M, Tofler GH, Sherwood JB, Goldberg RJ, Muller JE. Triggering of acute myocardial infarction by heavy physical exertion: protection against triggering by regular exertion. *N Engl J Med* 1993;329:1677-83.
4. Thompson PD, Franklin BA, Balady GJ, et al. Exercise and acute cardiovascular events placing the risks into perspective: a scientific statement from the American Heart Association Council on Nutrition, Physical Activity, and Metabolism and the Council on Clinical Cardiology. *Circulation* 2007;115:2358-68.
5. Parker B, Augeri A, Capizzi J, et al. Effect of air travel on exercise-induced coagulopathy and fibrinolytic activation in marathon runners. *Clin J Sport Med* 2011;21:126-30.

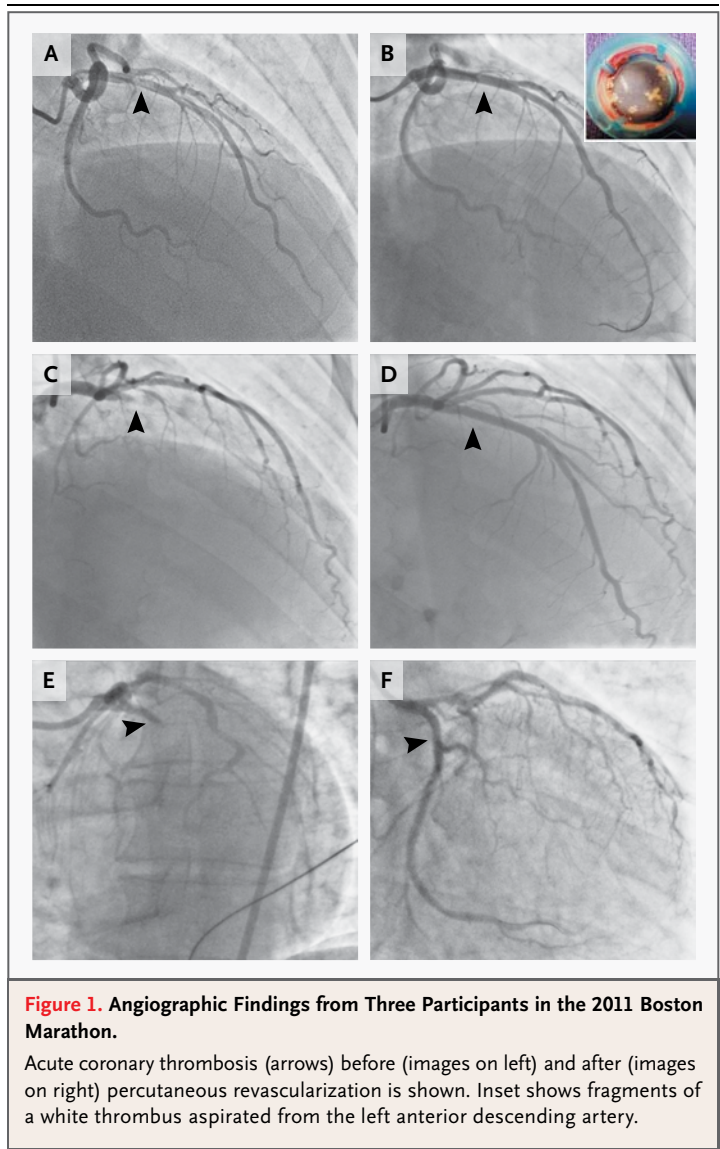


Figure 1. Angiographic Findings from Three Participants in the 2011 Boston Marathon.

Acute coronary thrombosis (arrows) before (images on left) and after (images on right) percutaneous revascularization is shown. Inset shows fragments of a white thrombus aspirated from the left anterior descending artery.

An Impedance Threshold Device in Out-of-Hospital Cardiac Arrest

TO THE EDITOR: Aufderheide et al. (Sept. 1 issue)¹ report on the logistically challenging, cluster-randomized Resuscitation Outcomes Consortium Prehospital Resuscitation Impedance Valve and Early Versus Delayed Analysis (ROC PRIMED; ClinicalTrials.gov number, NCT00394706) trial; they compared the use of an active impedance threshold device (ITD) with that of a sham device

in patients with out-of-hospital cardiac arrest. The study was conducted concurrently with a companion study of early rhythm versus later rhythm analysis. Patients were typically enrolled in both studies, which potentially delayed placement of the ITD. Use of the ITD did not improve survival with favorable neurologic function.

The interpretation of these results is prob-